

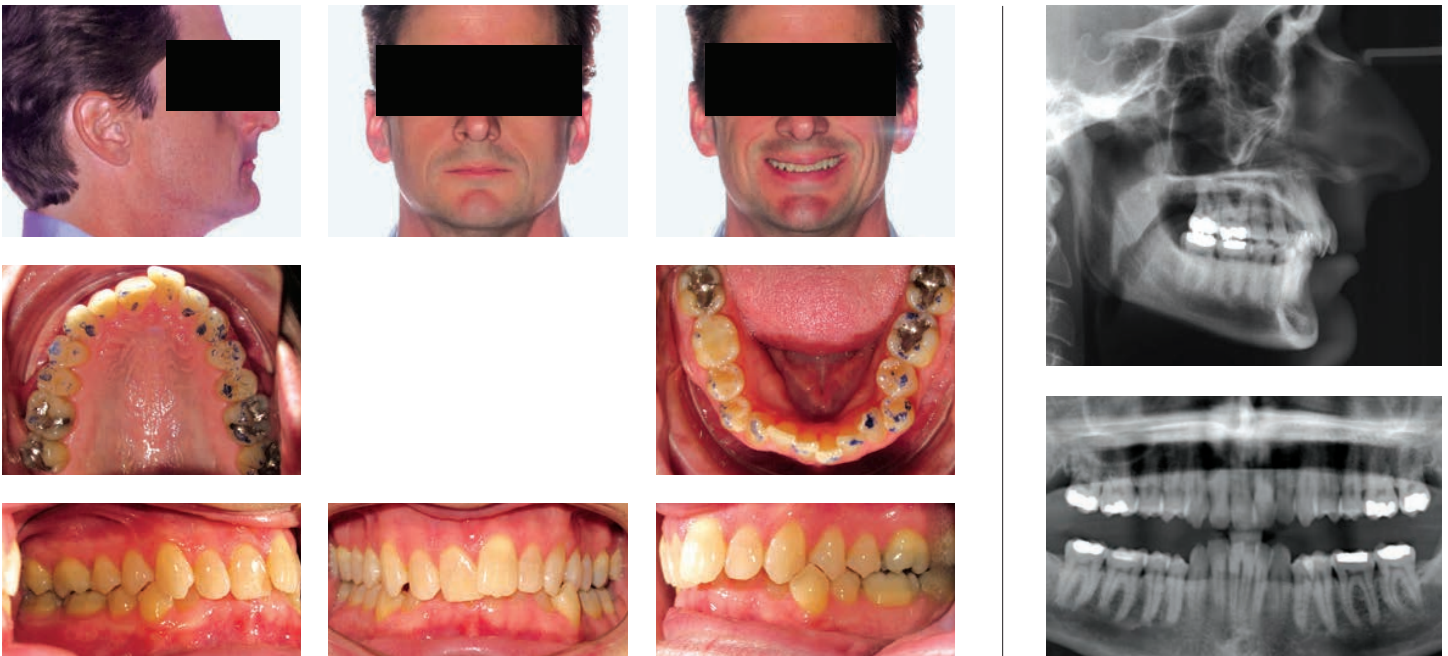

Approaching Severe Deep Bite Treatment with Invisalign® Clinical Innovations

Dr. Mazyar Moshiri

The vertical control of the Invisalign System is well known, and, in my opinion, increasingly becoming the method of choice with practitioners for effective management and closure of open bite malocclusions. However, using Invisalign to open the vertical dimension has been less popular, due to the perception that the appliance has difficulty producing the movements needed for deep bite correction, such as anterior intrusion. With the advent of improved aligner material, biomechanical considerations for proper force systems tested on the bench, and the ability to change the geometry in precise areas of the aligners to aid in certain tooth movements, opening of the vertical dimension is likely to become increasingly predictable.

The aim of this paper will be to demonstrate proper application of the new deep bite innovations introduced with Invisalign G5 using a patient currently in treatment. I will highlight the changes in thought process for treatment planning and ClinCheck® treatment plan setup given the new deep bite innovations.



CASE PRESENTATION: PATIENT JB

CC: "I'm concerned about the overlapping of my front teeth and lower crowding, and I would like to fix my bite."

Clinical History and Etiology: The patient was in good overall health at initial presentation. He had a history of several restorations due to caries.

Dental: Class I molar, class II canine bilaterally with 100% overbite, minimal overjet, maxillary midline to patient's left by 2 mm, mild crowding of upper arch, moderate crowding of lower arch, signs of lower anterior wear, with an exaggerated lower curve of Spee. Cephalometrically, upper incisors within normal limits (U1-SN 100) with upright lower incisors (IMPA 78).

Skeletal: Class I skeletal base (ANB 2.6), low mandibular plane angle (27).

Facial: Balanced profile with a strong chin.

Functional: Maximum interincisal opening 42 mm, right and left lateral excursive at 10 mm each. No deviations on opening, no joint noises present.

Treatment Goals: The treatment goals for JB were to help address his chief complaint—to alleviate his deep bite malocclusion while eliminating his upper and lower crowding. Given the accentuated mandibular curve of Spee, bite opening mechanics should be focused on the lower arch.

Treatment Planning Considerations

The treatment plan for JB will address his deep bite malocclusion with the following considerations:

1. A tooth size discrepancy (TSD) analysis for JB revealed 2.3 mm of mandibular excess from 6-6; this discrepancy should be addressed in order to properly detail his occlusion. IPR, while necessary, would be used sparingly to allow for flaring of lower incisors to normalize their position within basal bone, and in order to take advantage of natural bite opening from labial movement of the incisors. Natural bite opening as a result of labial incisor movement should be used as much as possible when treatment planning with Invisalign, as this movement occurs quite predictably.
2. As mentioned previously, bite opening mechanics for JB were focused on the lower arch due to his exaggerated lower curve of Spee and upright lower incisors. Additionally, given his smile line, upper incisor intrusion was not indicated as this would disturb the esthetics of his smile. After lower incisor crowding is corrected by proclination, absolute/pure intrusion would be used for the remainder of the deep bite correction.
3. In addition to intrusion, upper and lower lingual root torque should be increased to establish a more ideal interincisal angle to further facilitate bite opening and establish centric contacts at the lower incisal edges to improve long-term stability.

GENERAL CLINICHECK TREATMENT PLAN CONSIDERATIONS

Previous concerns surrounding the use of the Invisalign appliance with regards to deep bite malocclusions were due to lack of predictability for lingual root torque and incisor intrusion. The failure of these movements to express completely would result in heavy anterior centric contacts, and thus inhibit solid

posterior occlusion. These posterior open bites are the result of our mechanotherapy with Invisalign, and not from the simple presence of the aligners. When bite opening occurs posteriorly, it is an indication of either a side effect of a posterior movement (i.e., excessive expansion) or from heavy anterior centric contacts. Thus, it is necessary to exaggerate particular movements in the ClinCheck treatment plan (as one would with a reverse curve of Spee wire when using fixed appliances) in order to establish more predictable clinical outcomes. If, by circumstance, the movement does express as one would desire, the remaining aligners need not be delivered, and the patient's current aligner could be used as a "finishing" aligner, or refinement impressions/scans may be obtained.

Torque Correction

Cephalometric numbers should be used as an initial baseline to generate your treatment plan in order to guide how much lingual root torque is needed for correction of incisal angulations. In general, an extra 20% of lingual root torque than what is actually needed should be recommended when correcting upper incisors root torque; and, on the lower anterior teeth, about 10%. In my experience, lower anterior root torque expresses more predictably than upper lingual root torque with Invisalign.

For JB, upper incisor torque on the cephalogram was measured at near ideal, thus an additional 10 degrees of lingual root torque was requested to avoid tight anterior centric contacts. On the lower arch, an additional 14 degrees of lingual root torque were indicated cephalometrically, thus 16 degrees of torque was requested to be reflected in the ClinCheck treatment plan.

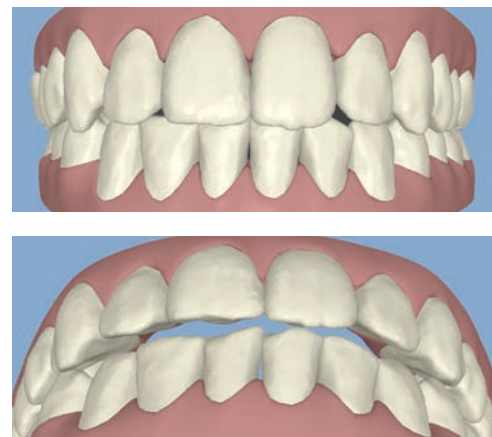


Figure 1. Demonstrating an overcorrection of lingual root torque in order to allow for sufficient opening of the deep bite, and absence of anterior centric contacts to allow for lack of anterior interferences post treatment

Anterior Intrusion

In order to properly level this patient’s lower curve of Spee, a significant amount of lower anterior intrusion would be required. The majority of desired intrusive movements should come secondary to incisor proclination (when possible) as the incisal edge position of proclined incisors are in a more gingival relationship, thus automatically opening the bite. Once desired incisor inclinations have been achieved, the remaining movements should then be pure intrusion.

Pure anterior intrusion has been a difficult movement to predict accurately with Invisalign. And, if the intrusion does not occur, the patient will experience heavy anterior centric contacts and lack of occlusion on the posterior teeth. Thus for JB, an exaggerated correction was requested on the ClinCheck treatment plan to help ensure movement would occur more predictably through treatment. In general, I like to request 2 mm of additional intrusion per indicated arch.

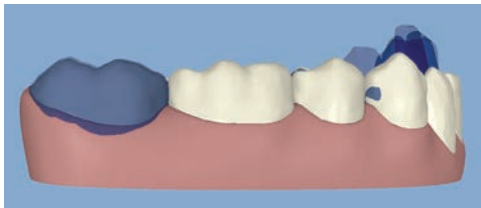


Figure 2. Demonstrating the final set-up of anterior intrusion, resulting in an exaggerated reverse curve of Spee. (The exaggerated step in the occlusion is not expected to occur clinically, but is requested for a more predictable clinical expression of desired intrusive movements.)

LEVERAGING G5 FEATURES TO ADDRESS JB’S DEEP BITE

In order to achieve proper deep bite correction, let’s consider the use of the new Invisalign G5 deep bite features:

Anterior Intrusion

Checking “intrude anterior teeth only” on the prescription form will add new lingual pressure areas, aligner features that will appear on upper or lower incisors and lower canines, providing a balancing intrusive force vector along the long axis of the tooth. This change in the geometry of the aligner has been bench tested and should provide a more accurate vector of force down the long axis of the incisor teeth being intruded. This will make intrusion of lower incisors a more predictable overall movement with Invisalign.

When filling out the prescription form for JB, I would request lower intrusion only.

B, J

7. Overbite

- Correct deep bite
 - Intrude anterior teeth only
 - Upper
 - Lower
 - Intrude anterior teeth and extrude premolars
 - Upper
 - Lower
 - Other (e.g. surgical simulation) specify in Special Instructions

Figure 3. The new prescription form, indicating my preference for addressing the deep bite through anterior intrusion on lower only for this particular case

In order to deliver significant amounts of anterior intrusion, the aligner has to push from the incisal edge in a vertical direction to the gingival through the long axis of the lower incisors. The effect of this force will result in a tendency of the aligner to lift off the posterior teeth. Thus, especially in the adult patient, anchorage delivered by sufficient retentive attachments is necessary to allow the aligner to express the desired intrusive forces anteriorly. In the past, my preference had been for horizontal rectangular attachments on all premolar teeth, and possibly the first molar, if a significant amount of intrusion was seen. Now a new generation of retention attachments will be triggered automatically to counteract the anterior intrusive force.

The new deep bite attachments for anchorage have been developed to provide sufficient but not excessive retention force while the anterior dentition is being intruded.

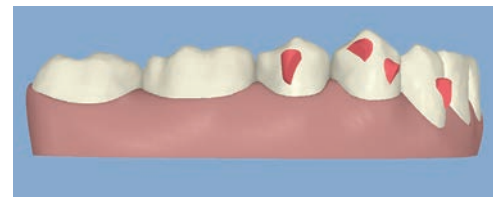


Figure 4. A rotation attachment has been placed on the 2nd premolar and will serve as anchorage; note that other attachments, such as optimized root control attachments, can also provide sufficient retentive anchorage

I did not elect to extrude premolars in addition to intruding the anteriors, as posterior extrusion should not be expected to occur in the non-growing patient; however, in the teenage patient, relative intrusion of the incisors from extrusion of the buccal segment is a reasonable assumption. If premolar extrusion is chosen by the practitioner (i.e. for a growing patient), the retentive attachments on the premolars will be made with an active surface to aid in relative extrusion of the buccal segment during anterior intrusion.

Bite Ramps

When filling out the prescription form for JB, I would also ask for bite ramps:

B, J

8. Bite Ramps (Protrusions on the aligner for disoccluding posterior teeth)

None

Place Bite Ramps on lingual of these upper teeth

Incisors (Caution: Bite Ramps and Anterior Intrusion features cannot co-exist on the same tooth)

Central incisors

Lateral incisors

Canines

Figure 5. Prescription form showing Question 8, for placement of bite ramps

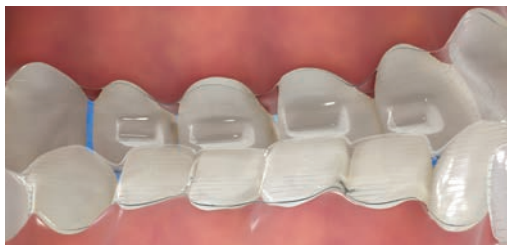

Figure 6. An illustration showing how Precision bite ramps might look from the lingual perspective. Note that placement of the bite ramps will override the placement of the pressure areas, as both features cannot co-exist in the same place on the lingual aspect of the aligners.

Prior to Precision bite ramps, which have been introduced with Invisalign G5, some doctors requested *conventional* bite ramps on their aligners. Conventional bite ramps are also unfilled prominences of the aligner material lingual to the maxillary incisors, and have proven helpful in correction of deep bite malocclusions with Invisalign. Presumably, the bite forces of the lower incisors resting upon the bite ramps facilitates the required anterior intrusion. Additionally, when applying lingual root torque, the aligners have a tendency to squeeze away off of the anterior teeth. Again, the constant seating force against the lingual bite ramps may force the aligner back onto the teeth, allowing for maxillary incisor lingual root torque movements to express more fully.

One drawback to conventional bite ramps is that they cannot be placed at varying heights, which would be helpful for patients whose lower anterior incisal edges vary due to crowding. Additionally, the prominence of conventional bite ramps does not change during treatment to remain in constant contact with

lower incisor edges as the level changes. The new Precision bite ramps, when requested to be present, will be made stageable at initial onset and change as treatment progresses to remain in constant contact with the lower incisors. With these new features of Precision bite ramps, the welcome effect of the bite ramps would be more persistent through JB's treatment. In addition, the prescription form now offers the option to trigger their placement from the outset versus requesting them after the initial ClinCheck treatment plan set-up.

Retention Considerations

If a patient with a deep bite malocclusion is finished with a stable posterior occlusion and appropriate interincisal angle with light centric contacts, Vivera® retention is a great choice for retention of the corrected deep bite malocclusion.

However, if the patient has strong facial musculature, needs posterior settling of their occlusion, or if there was a significant amount of lower anterior intrusion, a Hawley retainer with an anterior bite plate effect is an appropriate retention choice that allows for some settling of the posterior occlusion, if needed, and aids in reinforcement of the intrusive force on the lower incisors during retention.

DR. MAZYAR MOSHIRI

Dr. Mazyar Moshiri maintains his private practice in St. Louis, MO., where he is an Invisalign Elite Provider. He is an Assistant Clinical Professor at the Saint Louis University Center for Advanced Dental Education, where his lectures and clinical oversight focus on the Invisalign appliance system. Dr. Moshiri is a Diplomate of the American Board of Orthodontics and a Fellow, American College of Dentists.

DISCLOSURE

Dr. Moshiri was provided an honorarium from Align for his presentation. The statements, views and opinions expressed in this presentation are those of the author, and do not necessarily reflect the views and opinions of Align Technology, Inc.